New Minimally Invasive Glaucoma Surgery Options

Leon W. Herndon Jr., MD

Developed in collaboration

Med-IQ DukeHealth

What Is MIGS?

- Smart weapons, targeting the enemy, with minimal to no collateral damage
- Ab interno
- Must have minimal alteration of the tissue
  - No conjunctival incision
- Must be safe
- At least modestly efficacious
- Rapid recovery

Fingeret M, et al. *Optom Vis Sci*. 2018;95:155-62.

Bleb Complications

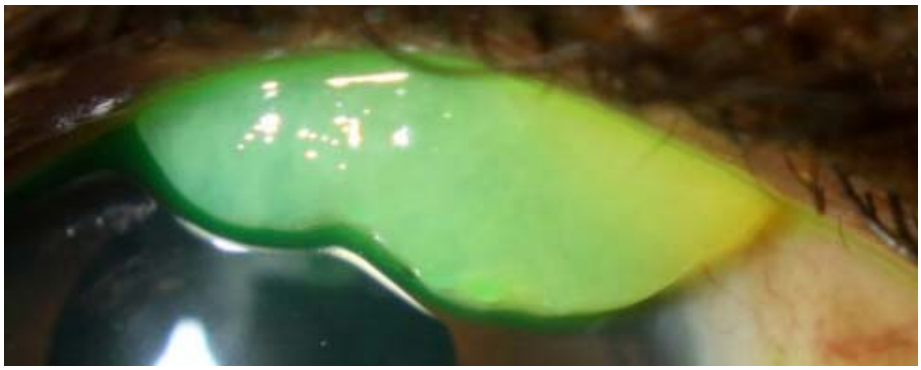

Glaucoma Surgery: The New Frontier

- MIGS is preeminent in the minds of doctors, patients, industry, and the ophthalmology media
- With so much churning in the ophthalmic field, how can we find clarity and establish practice patterns?
- Can we practice evidence-based medicine?
- How do we pick the right procedure for any given patient?
- Can we individualize the treatment of glaucoma?
- How many different treatment modalities can one surgeon handle?

MIGS—A New Philosophy

- Glaucoma surgery was reserved for patients losing vision despite maximum medical therapy
- Reserving it as a last resort was appropriate because of the high associated risks
- The hallmark of MIGS, however, is safety

Francis BA, et al. *Ophthalmology*. 2011;118:1466-80.

Patient Profiles: New Procedures

MIGS-Type Procedures

Ab Interno Schlemm's/Suprachoroidal

- Mild-moderate disease
- Open-angle
- Modest IOP target (ie, 15-16 mm Hg)
- Able to tolerate some meds





Trabeculectomy-Type Procedures

- Moderate-advanced disease
- Progressing normal pressure glaucoma
- Open or narrow angle
- Low IOP target (ie, < 13 mm Hg)
- Intolerant to most meds



Saheb H, et al. *Curr Opin Ophthalmol.* 2012;23:96-104.

Implant Placement

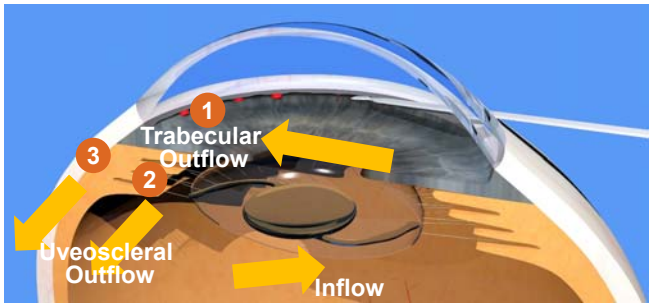

1. Trabecular Micro-Bypass/ Schlemm's Canal
2. Suprachoroidal Space
3. External Bypass/ Subconjunctival Space

Gedde SJ, et al. *Am J Ophthalmol.* 2012;153:789-803.

Overview of the MIGS Landscape

	FDA PMA	MIGS CLASS
Glaukos iStent	2012	Trabecular Micro-Bypass
Glaukos iStent *Inject*	2018	Trabecular Micro-Bypass
Ivantis Hydrus	2018	Trabecular Bypass
Alcon CyPass	2016	Suprachoroidal
Allergan Xen	2016	Subconjunctival/External

Fingeret M, et al. *Optom Vis Sci.* 2018;95:155-62.

Overview of the MIGS Landscape

	CLASS
Ellex ABiC **Sight Sciences** Visco360; Omni	Canal/Trabecular Dilation
New World Medical Kahook Dual Blade (KDB) **Sight Sciences** Trab360; Omni	Trabecular Meshwork Removal
NeoMedix Trabectome	Trabecular Meshwork Removal

BEST HOSPITALS U.S.News HONOR ROLL 2018-19

DukeHealth

Putting MIGS Into Perspective



BEST HOSPITALS U.S.News HONOR ROLL 2018-19

DukeHealth

MIGS Approaches: Trabecular Micro-Bypass

Second-Generation Trabecular Micro-Bypass Injector

- Heparin-coated titanium
- Dimensions: 360 x 230 µm with radial symmetry
- Injected through the trabecular meshwork into Schlemm's canal
- Treatment consists of implantation of two stents

Fingeret M, et al. *Optom Vis Sci*. 2018;95:155-62.

Second-Generation Trabecular Micro-Bypass Procedure

- Step 1. Approach perpendicular to the tissue
- Step 2. Penetrate the tissue with trocar
- Step 3. Lightly press on the TM (or dimple), hold steady, then deploy stent

Package insert.

One, Two, or Three Trabecular Bypass Stents Standalone

Dose-Response Study

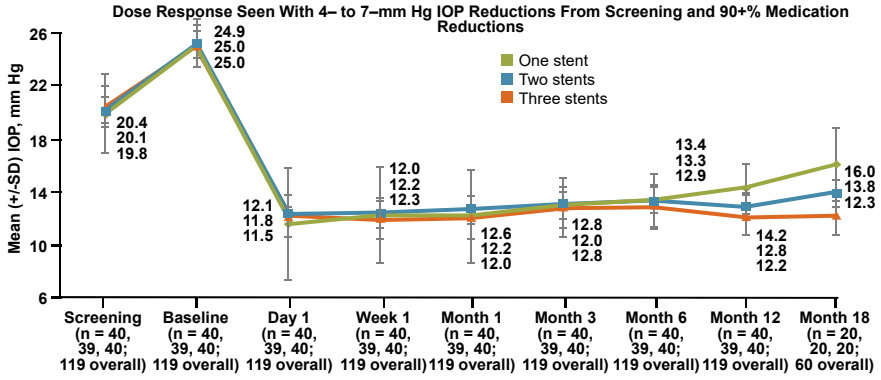

Note: final numbers in manuscript different than this graph.
Katz LJ, et al. *Clinical Ophthalmology*. 2015;9:2313-20.

Trabecular Bypass Stent Standalone or + Phaco in Naïve or Prior Glaucoma Surgery Patients

Case Series—IOP Through 18M

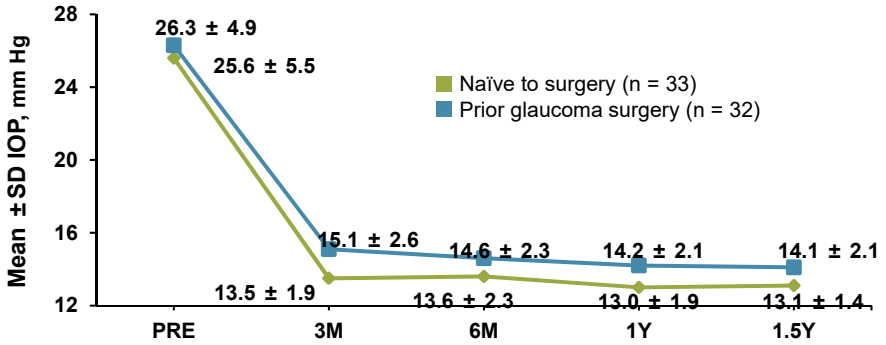

Naïve Eyes: 12.5–mm Hg IOP decrease (47% reduction)
Eyes With Prior Sx: 12.2–mm Hg IOP decrease (45% reduction)

Hengerer F. Poster presented at AAO 2016; Chicago, IL.

BEST HOSPITALS U.S.News HONOR ROLL 2018-19

DukeHealth

Postoperative Adverse Events

Postoperative Events	Cataract Surgery With Trabecular Bypass Stent N = 386 n (%)	Cataract Surgery Only N = 119 n (%)
Ocular surface disease	62 (16.1%)	20 (16.8%)
Stent obstruction, partial or complete, regardless of how long the obstruction is present	24 (6.2%)	NA
Any intraocular inflammation (non-preexisting) remaining or arising after the protocol's specified medication regimen is complete	22 (5.7%)	5 (4.2%)
Secondary surgical intervention	21 (5.4%)	6 (5.0%)
Ocular allergies	11 (2.8%)	4 (3.4%)
Loss of BSCVA of 2 lines or more (10 letters or more on ETDRS chart) at or after 3 months postoperative	10 (2.6%)	5 (4.2%)
Posterior vitreous detachment	10 (2.6%)	5 (4.2%)
Foreign body sensation	9 (2.3%)	0 (0.0%)
Blurred vision/visual disturbance	9 (2.3%)	2 (1.7%)
Extraocular inflammation	9 (2.3%)	2 (1.7%)
Epiretinal membrane	9 (2.3%)	3 (2.5%)
IOP increase ≥ 10 mm Hg vs baseline IOP occurring at ≥ month 1	8 (2.1%)	1 (0.8%)
Perioperative ocular pain within 14 days of surgery	8 (2.1%)	1 (0.8%)
Vitreous floaters	9 (2.1%)	3 (2.5%)
Corneal abrasion	8 (2.1%)	4 (3.4%)

Package insert.

BEST HOSPITALS U.S.News HONOR ROLL 2018-19

DukeHealth

Schlemm's Canal Microstent Overview

Evolution of Canal Stenting

iSTENT (2012)

BYPASS

iSTENT INJECT (2018)

BYPASS + ADDED COVERAGE

HYDRUS MICROSTENT (2018)

BYPASS + 90° SPAN + SCAFFOLD

Package insert.

Schlemm's Canal Microstent: Ab Interno Canal-Based MIGS

Tri-Modal Mechanism of Action

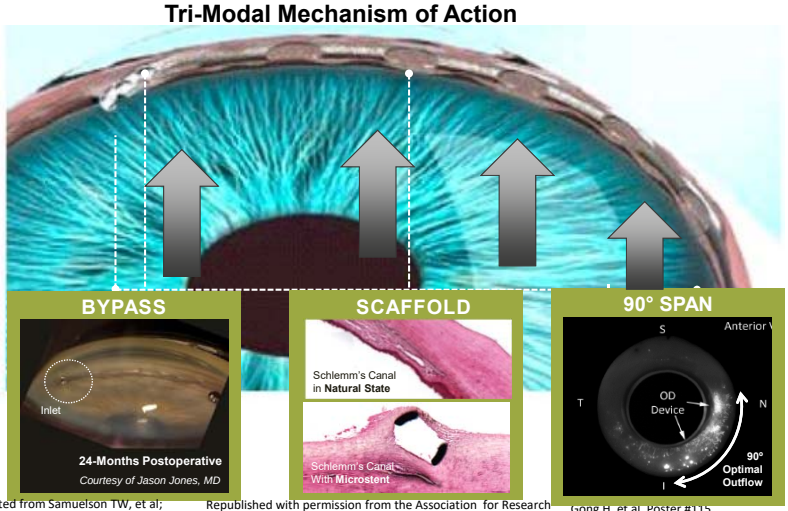

Reprinted from Samuelson TW, et al; HORIZON Investigators. *Ophthalmology*. In press with permission from Elsevier

Republished with permission from the Association for Research in Vision and Ophthalmology. Hays CL, et al. *Invest Ophthalmol Vis Sci*. 2014;55:1893-900; permission conveyed through Copyright Clearance Center Inc.

Gong H, et al. Poster #115. American Glaucoma Society; 2012; NY

Brandao L et al. J Opthalmol. 2013; 2013:705915

Schlemm's Canal Microstent

View From Anterior Chamber

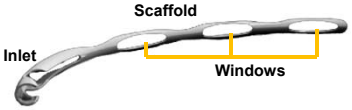

View From Canal

- Flexible, biocompatible, 8 mm–long microstent
- Made out of nitinol (highly biocompatible material used in cardiovascular stents)
- Contoured to match canal curvature
- Three open windows face anterior chamber
- The canal-facing surface is completely open for unobstructed collector channel access

Package insert.

Real-Time Confirmation of Accurate Delivery

Video courtesy of I. Paul Singh, MD.

BEST HOSPITALS U.S.News HONOR ROLL 2018-19

DukeHealth

Reliable & Efficient Access to Multiple Collector Channels

Dye Test Verifies Outflow in Stented Quadrant

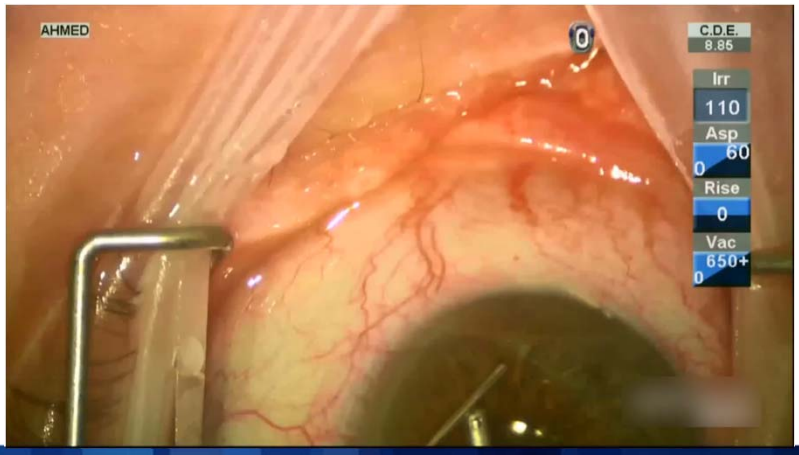

Video courtesy
of Ike Ahmed, MD

BEST HOSPITALS U.S.News HONOR ROLL 2018-19

DukeHealth

HORIZON Clinical Trial

Overview

HORIZON: Largest Ever MIGS Pivotal Trial

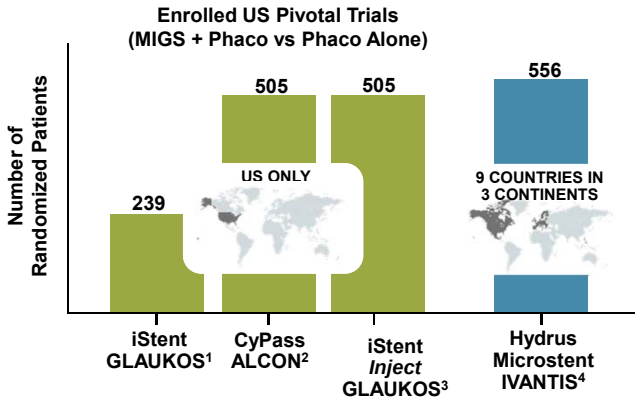

1. Package insert. 2. Vold S, et al. *Ophthalmology*. 2016;123:2103-12. 3. Package insert. 4. Samuelson TW, et al. *Ophthalmology*. In press.

BEST HOSPITALS U.S.News HONOR ROLL 2018-19

DukeHealth

HORIZON Trial: Study Design

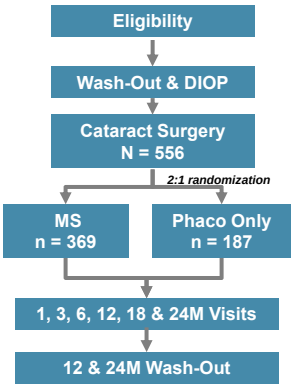

- **Inclusion:** *Mild/moderate* POAG (VF MD ≥ 12 dB), cataract, 1-4 medications, no prior glaucoma surgery, ± prior SLT
- **After 4-week wash-out:** mean DIOP 22-34 mm Hg
- **Treatment**: 2:1 randomization in the OR to MS or phaco only after successful PC IOL
- **Primary endpoint**: 20% reduction in washed-out DIOP at 24 months
- **Secondary endpoint:** Change in mean washed-out DIOP at 24 months
- **Medications:** mean and counts at each visit
- **Statistics:** > 90% power for primary endpoint; ITT analysis

Kuldev Singh, MD, MPH, Medical Monitor

Samuelson TW, et al; HORIZON Investigators. *Ophthalmology*. In press.

Demographics and Preoperative Status

Patient Characteristic	MS n = 369	No Stent n = 187
Age, years	71.1 ± 7.9	71.2 ± 7.6
OD study eye, %	48.2%	49.2%
Ethnicity		
Asian	5.7%	5.9%
Black or African	12.2%	8.0%
Caucasian	78.9%	81.8%
Other	3.3%	4.3%
Glaucoma medications		
1	52.6%	54.0%
2	27.1%	25.7%
3	17.6%	15.0%
4	2.7%	5.3%

Ocular and Glaucoma Status	MS n = 369	No Stent n = 187
BCVA, mean	20/40	20/40
VF, MD	-3.6 ± 2.5	-3.6 ± 2.6
Corneal thickness, μ	548 ± 32	549 ± 35
Prior SLT	15.7%	15.0%
Medicated IOP, mm Hg (mean medications)	17.9 ± 3.1 (1.7)	18.1 ± 3.1 (1.7)
Washed-out DIOP, mm Hg	25.5 ± 3.0	25.4 ± 2.9

Samuelson TW, et al; HORIZON Investigators. *Ophthalmology*. In press.

BEST HOSPITALS U.S.News HONOR ROLL 2018-19
DukeHealth

HORIZON: Primary Endpoint

20% Reduction in Washed-Out DIOP

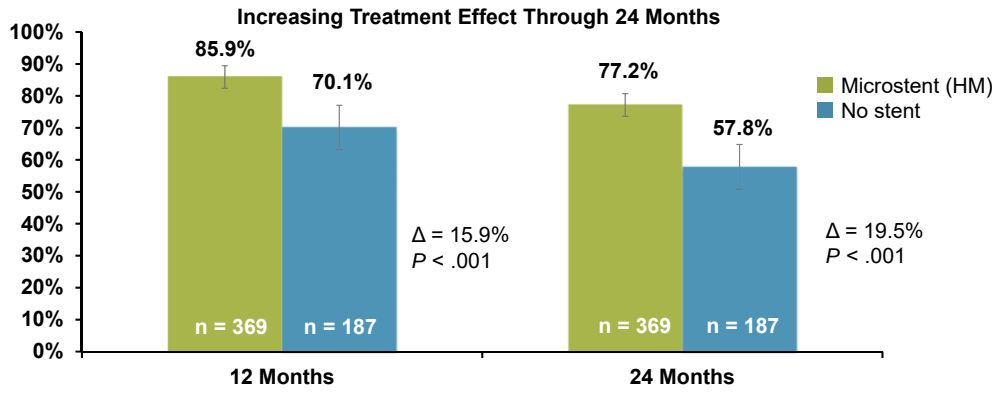

Reprinted from Samuelson TW, et al; HORIZON Investigators. *Ophthalmology*. In press with permission from Elsevier

ITT analysis
I-bars represent 95% confidence intervals

BEST HOSPITALS U.S.News HONOR ROLL 2018-19

DukeHealth

HORIZON: Secondary Endpoint

Change in Washed-Out DIOP

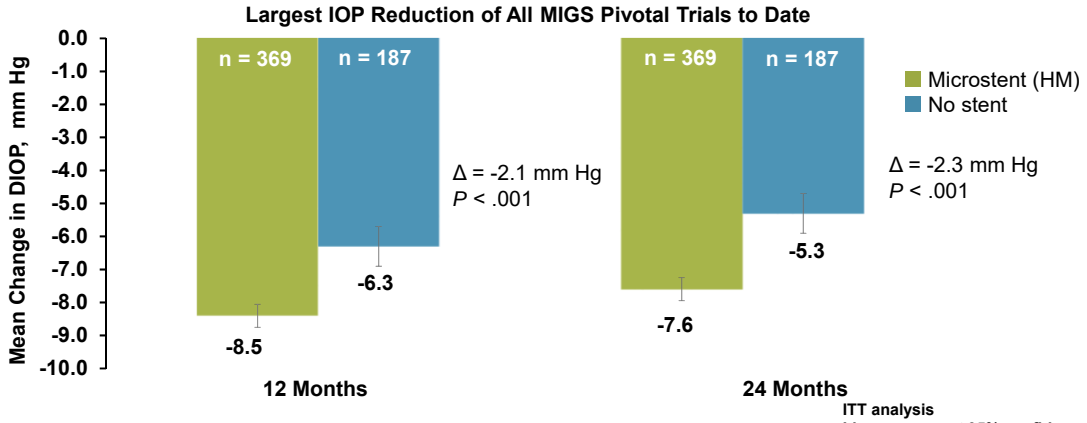

ITT analysis
I-bars represent 95% confidence intervals

Reprinted from Samuelson TW, et al; HORIZON Investigators. *Ophthalmology*. In press with permission from Elsevier; Vold S, et al. *Ophthalmology*. 2016;123:2103-12; Package inserts

BEST HOSPITALS U.S.News HONOR ROLL 2018-19

DukeHealth

HORIZON: Medication-Free

Medication-Free 0-24 Months

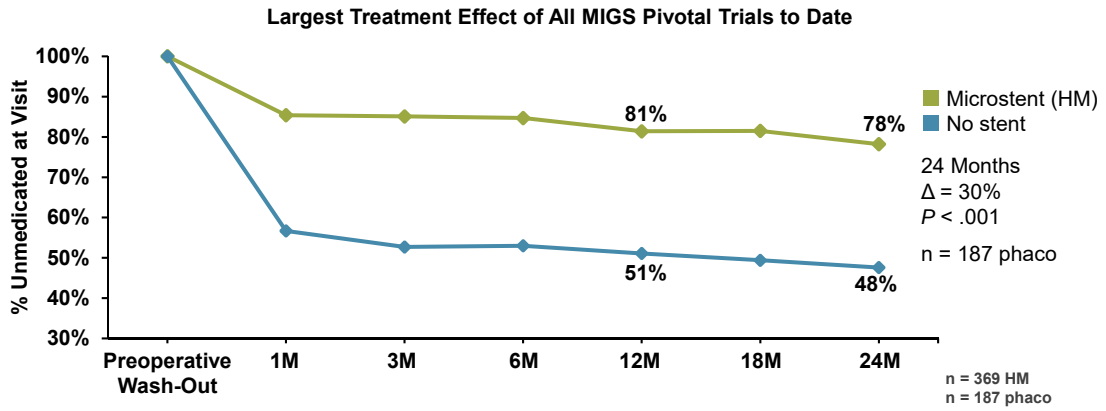

Reprinted from Samuelson TW, et al; HORIZON Investigators. *Ophthalmology*. In press with permission from Elsevier; Vold S, et al. *Ophthalmology*. 2016;123:2103-12; Package inserts

Cumulative Adverse Events Through 24 Months

Intraoperative Events	MS n = 369	No Stent n = 187
Device malposition	1.6%	0
Hyphema	1.1%	0
Postoperative events	**MS n = 369**	**No Stent n = 187**
IOP-related events	0.8%[a]	5.8%
Trabeculectomy/GDD	0	2.1%
IOP spike (> 10 mm Hg over baseline > 30 days)	0.5%	2.7%
Paracentesis > 7 days	0.3%	0.5%
Hypotony ≤ 6 mm Hg ≥ 1 day	0	0
Uveitis/iritis requiring steroids	5.6%	3.7%
Layered hyphema, > 2 mm > 1 day	0.5%	0.5%
Laser synechialysis	0.8%	0
Tissue obstruction/obstructive PAS	3.8%	0

[a]*P* < .05 vs control.
Samuelson TW, et al; HORIZON Investigators. *Ophthalmology*. In press.

Med-IQ®

DukeHealth

BEST HOSPITALS U.S.News HONOR ROLL 2018-19

DukeHealth

MIGS: Abbreviations and Acronyms

BSCVA = best spectacle-corrected visual acuity
DIOP = diurnal intraocular pressure
ETDRS = Early Treatment Diabetic Retinopathy Study
GDD = glaucoma drainage device
HM = Hydrus microstent
IOP = intraocular pressure
ITT = intention-to-treat
MD = mean deviation
MIGS = minimally invasive glaucoma surgery
MS = microstent
OD = oculus dexter (right eye)
OR = operating room
PAS = peripheral anterior synechiae
PC IOL = posterior chamber intraocular lens
PMA = premarket approval
POAG = primary open-angle glaucoma
SD = standard deviation
SLT = selective laser trabeculoplasty
TM = trabecular meshwork
VF = visual field